

AIRWAY DISEASE

Subglottic stenosis following percutaneous tracheostomy: a single centre report as a descriptive study

Stenosi sottoglottica in esiti di tracheotomia percutanea: report del nostro centro

K. KARVANDIAN, A. JAFARZADEH, A. HAJIPOUR, N. ZOLFAGHARI

Anaesthesiology Department and Intensive Care Unit, School of Medicine, Tehran University of Medical Sciences, Imam Khomainsi Hospital, Tehran, Iran

SUMMARY

Tracheal stenosis is a potential complication of tracheostomy. The present study aimed to describe the epidemiologic profile of subglottic stenosis in a referral medical centre. During a 4-year period, all patients who had been admitted in an Intensive Care Unit of Imam Khomeini Hospital (affiliated to Tehran University of Medical Sciences) and had undergone percutaneous tracheostomy during 7-10 days after endotracheal intubation were enrolled in the study. After removing the tracheostomy tube, patients were evaluated regarding development of tracheal stenosis using fiberoptic bronchoscopy and multi-slice computed tomography scan. During the study period, percutaneous tracheostomy was performed in 140 patients with a mean age of 38 years. Overall 54 patients died due to the severity of the disorder during hospitalization. In the remaining 86 patients, 54 cases needed permanent or long-term mechanical ventilation and were excluded from the study. Twelve patients died during the first 3 months and 20 patients were left for final assessment. Multi-slice computed tomography scan imaging showed subglottic stenosis in 17 cases (85%). Of these, 9 patients (52%) had tracheal stenosis of < 50%. Tracheal stenosis of 25-40% was found in 5 cases (25%). Patients in whom the tracheostomy tube had been removed in the first 3 weeks after tracheostomy did not present tracheal stenosis (n = 3, 15%). The present study revealed that subglottic stenosis is frequent in patients who have undergone percutaneous tracheostomy in the Intensive Care unit setting. However, the stenosis is generally mild and is not associated with serious and/or life-threatening clinical manifestations.

KEY WORDS: Percutaneous tracheostomy • Intensive Care Unit • Subglottic stenosis

RIASSUNTO

La stenosi tracheale è una possibile complicanza della tracheotomia. Scopo del presente studio è di descrivere il profilo epidemiologico delle stenosi sottoglottiche in un centro ospedaliero di riferimento di secondo livello. Sono stati studiati tutti i pazienti che in un periodo di 4 anni sono stati sottoposti a tracheotomia percutanea presso la Terapia Intensiva dell'Ospedale Iman Khomeini (affiliato all'Università di Scienze Mediche di Tehran) nei 7-10 giorni successivi all'intubazione endotracheale. Dopo la rimozione della cannula tracheale, i pazienti sono stati valutati mediante broncoscopia a fibre ottiche e tomografia computerizzata multi-slice per evidenziare la presenza di stenosi tracheale. Durante il periodo considerato, la tracheotomia percutanea è stata eseguita in 140 pazienti (età media: 38 anni) di cui 54 sono deceduti durante il ricovero a causa della patologia determinante l'ospedalizzazione. Dei restanti 86 pazienti, 54 hanno avuto la necessità di mantenere la tracheotomia a permanenza per proseguire la ventilazione meccanica, e sono stati pertanto esclusi dallo studio. Nei primi 3 mesi 12 pazienti sono morti, per cui sono giunti alla valutazione finale 20 pazienti. La Tomografia Computerizzata Multi-slice ha evidenziato la presenza di una stenosi tracheale in 17 casi (85%), in 9 di essi (52%) la stenosi era < 50%, mentre una stenosi tracheale del 25-40% è stata riscontrata in 5 casi (25%). Nessuno dei pazienti in cui la tracheotomia è stata rimossa entro le prime tre settimane dall'intervento ha presentato una stenosi tracheale (3 casi, pari al 15%). In conclusione il presente studio mette in evidenza come la tracheotomia percutanea determini frequentemente una stenosi tracheale sottoglottica. Tuttavia nella maggior parte dei casi la stenosi è di lieve entità e non determina pertanto conseguenze clinicamente significative per il paziente.

PAROLE CHIAVE: Tracheotomia percutanea • Terapia Intensiva • Stenosi sottoglottica

Acta Otorhinolaryngol Ital 2011;31:239-242

Introduction

Tracheostomy is routinely performed in critically ill patients needing mechanical ventilation for a long period¹. Tracheostomy can be performed using conventional surgical techniques or modern percutaneous procedures. Today, percutaneous dilational tracheostomy (PDT) which

was introduced, in 1985, by Ciaglia et al.² is widely used. Percutaneous tracheostomy (PCT) is considered to be safer and more cost-effective than conventional tracheostomy^{3,4} and can be performed earlier in the ventilator failure situations⁵. Several techniques have been introduced for PCT⁶⁻⁸. Despite the limitations of PCT, most tracheosto-

mies are currently performed using the PCT techniques in intensive care medicine ⁹.

In spite of its high level of safety, severe complications have been reported following PCT ¹⁰. Tracheal stenoses, including subglottic stenosis, are one of the serious complications of PCT which may require surgical repair ¹¹. Moreover, other types of tracheal injury, such as internal deviation of the tracheal cartilage, have been reported following PCT ¹².

There are a few reports from the Middle East regarding safety and serious complications of PCT including tracheal stenosis ¹³⁻¹⁵ and there is a lack of data in this regard. The present study aimed to describe the epidemiologic profile of subglottic stenosis in patients undergoing PCT in an intensive care unit (ICU) in a referral hospital in Tehran, Iran.

Material and methods

After approval of the Institutional Review Board of the Tehran University of Medical Sciences, this prospective study was conducted at the Imam Khomeini Hospital, a referral centre in Tehran, from October 2006 to March 2010. All patients aged > 12 years who were admitted to the ICU, and who underwent PCT, 7-10 days after endotracheal intubation, were enrolled in the study. Patients with a malignant tumour invading the trachea, tracheal compression by cervical or thoracic structures, severe tracheal injury, previous cervical surgery, serious coagulation disorders and needing emergency tracheostomy were excluded. Before performing tracheostomy, upper airway structures were assessed using flexible bronchoscopy and patients with structural anomalies in their upper respiratory tract were also excluded.

All tracheostomies were performed in the ICU by an expert, at the bedside and under general intravenous anaesthesia. Anaesthesia was induced using fentanyl (0.05 to 0.20 µg/kg), propofol (5-10 mg) and atracurium bromide (50-100 mg). If necessary, before starting the procedure, the positive end-expiratory pressure (PEEP) was reduced stepwise to 5 cm H₂O. The patient's neck was slightly reclined and the surgical site was cleansed with antiseptic agents. A flexible fiberoptic bronchoscope was used in all cases. PCT was performed using Ciaglia's technique ¹⁶. The tracheostomy tubes used for PCT were 7.0 mm (n = 65) and 8.0 mm (n = 85) in internal diameter (Portex, Smiths Medical, Hythe, UK).

Immediately after tracheostomy, correct placement of the tube was confirmed by bilateral auscultation of lungs, measurement of end tidal CO₂, tidal volume and chest X-ray. Arterial blood gas was obtained at the end of the procedure and all short-term and long-term changes in clinical conditions were carefully monitored during and following the procedure.

Patients in whom the tracheostomy tube was removed and who survived 4 months after leaving hospital were assessed regarding development of tracheal stenosis using a flexible fiberoptic bronchoscope plus multi-slice CT scan (GE,

USA). The CT scan device gathered 64 slices at 0.625 mm and provided 3D images of the trachea.

Results

During the study period, 140 patients including 85 males (mean age 33 years) and 55 females (mean age 45 years (overall mean age 38 years) were enrolled in the study. Median duration of tracheostomy was 9 weeks (range 5-19). A total of 54 patients died during hospitalization due to the severity of the disorder. In the remaining 86 patients, decannulation was not possible in 54 cases since they needed permanent or long-term mechanical ventilation. These patients were then excluded from the study. Furthermore, 8 and 4 died, respectively, one and three months later, none of them were secondary to respiratory disorders including tracheal stenosis. The remaining 20 patients were assessed regarding the presence of tracheal stenosis. One tracheo-bronchial fistula was observed during the first month of follow-up.

Transient tracheal stenosis developed in one patient known to be suffering from *myasthenia gravis* and needed mechanical ventilation for 4 months. The stenosis was position-dependent and the trachea was obstructed when the patient rotated her neck to the right (Fig. 1). Multi-slice CT scan imaging showed subglottic stenosis in 17 cases (85%). Nine of 17 patients (53%) suffered from subglottic stenosis with < 50% at the site of tracheostomy tube insertion. Tracheal stenosis of 25-40% was found in 5 cases (25%). Internal deviation of the lower tracheal ring was found in one patient that was however symptom free. Tracheo-mediastinal fis-

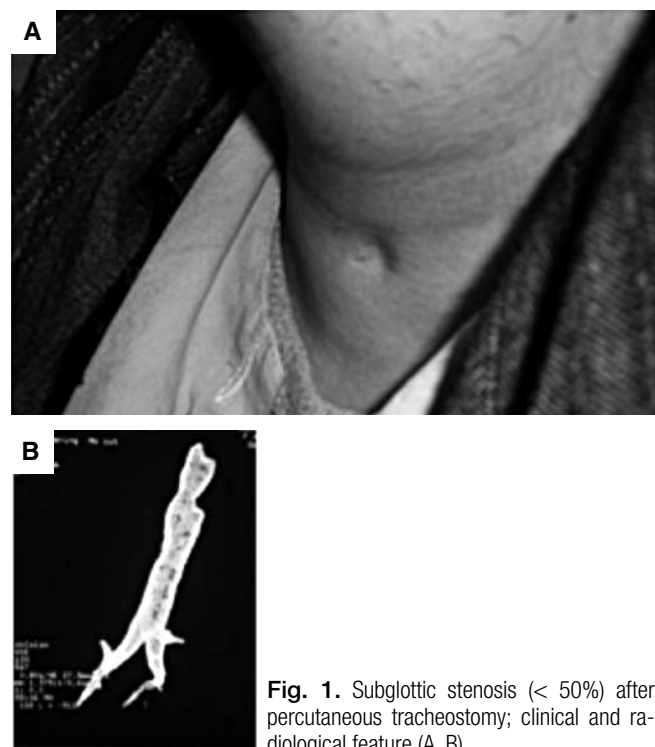


Fig. 1. Subglottic stenosis (< 50%) after percutaneous tracheostomy; clinical and radiological feature (A, B).

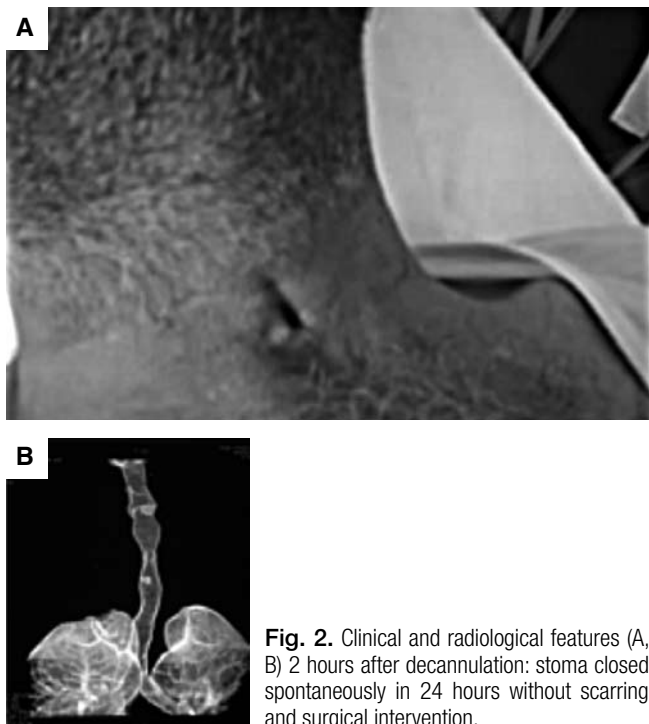


Fig. 2. Clinical and radiological features (A, B) 2 hours after decannulation: stoma closed spontaneously in 24 hours without scarring and surgical intervention.

tula was another complication which was observed in one patient. The patient had advanced lung disease and died 7 months later due to sepsis. Patients in whom the tracheostomy tube had been removed within the first 3 weeks after tracheostomy did not present tracheal stenosis ($n = 3, 15\%$). Details are shown in Figure 2.

Using 64-slice CT scan, 9 of 20 patients evaluated had subglottic stenosis with $< 50\%$ in the site of tracheostomy tube insertion that had involved tracheal cartilage rings. Tracheal stenosis was not found in the lower parts of the trachea which might be related to cuff pressure or other injuries (Fig. 3).

Discussion

Tracheal stenosis after tracheostomy can develop at microscopic and macroscopic levels. Although microscopic stenosis occurs in almost all cases, clinically significant macroscopic stenosis develops when the tracheal stenosis is $> 50\%$ ¹¹. Tracheal stenosis is the most serious long-term complication of PCT and can be life threatening. Surgical reconstruction of the tracheal stenosis is effective; however, in some cases subglottic stenosis develops which requires greater surgical skills. Moreover, some cases need lifelong intermittent dilation or permanent tracheostomy. These facts indicate that early detection of tracheal stenosis is essential in order to perform more effective interventions¹². The incidence of tracheal stenosis does not appear to vary between the different techniques of tracheostomy^{8,17}. It has been suggested that puncturing of the anterior wall of the tracheal and cartilage fractures is probably responsible for the subglottic stenosis following PCT¹¹.

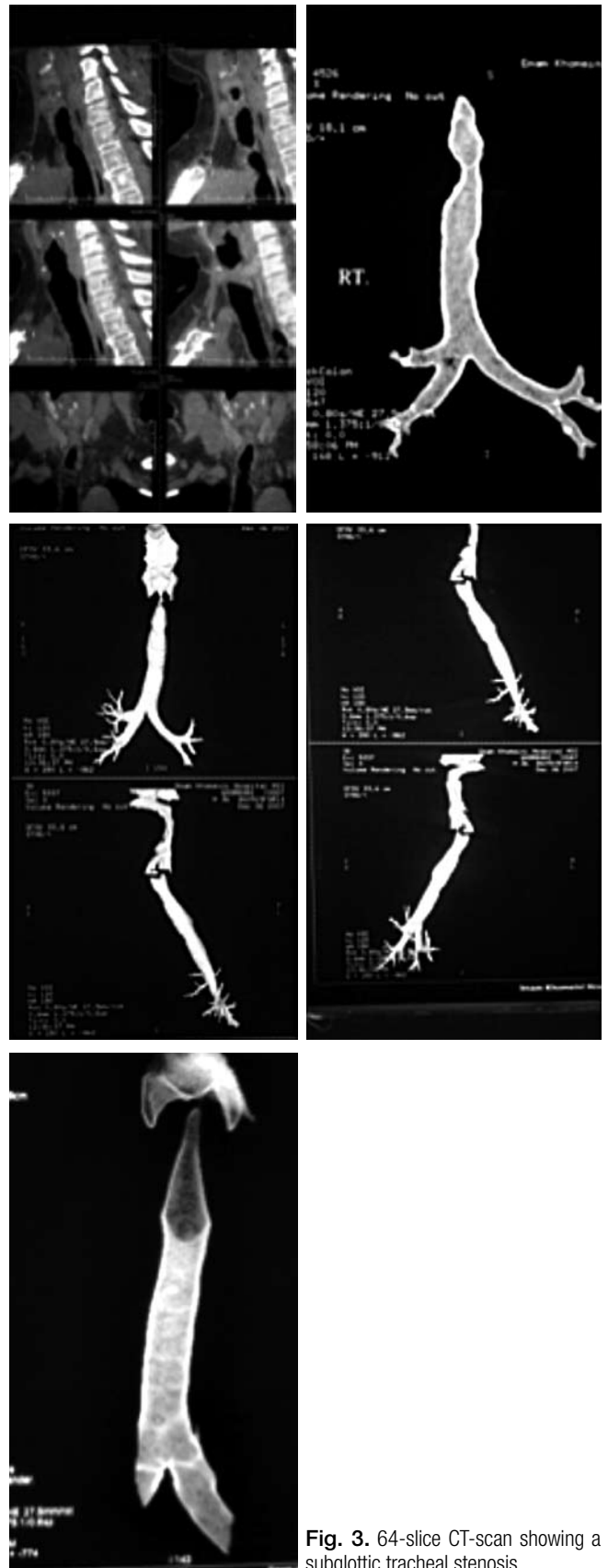


Fig. 3. 64-slice CT-scan showing a subglottic tracheal stenosis.

In our series, subglottic stenosis occurred in 17 cases (85%) and tracheal stenosis was 25-40% in 5 cases (25%). Tracheal stenosis of $< 50\%$ was found in 45% of all patients.

These numbers are relatively similar to the study conducted by Dollner et al.¹⁸ These Authors reported clinically relevant tracheal stenoses in one patient out of 38 patients studied following Griggs tracheostomy. Tracheal stenosis, less than 25% without clinical symptoms, was found in 89.5% (34/38) of the cases¹⁸. However, the development of tracheal stenosis, in our study, was much higher than the numbers reported by other authors¹⁹. In the study by Ciaglia and Graniero¹⁹, of the 54 cases of decannulation, the Authors reported 10-15% tracheal stenosis in 11, 25-50% stenosis in 2 and > 50% stenoses in one. Asymptomatic stenosis was observed in 10% of the cases studied. The difference may be due to the different diagnostic modalities used.

There is controversy regarding the best modality for diagnosis of tracheal stenosis following tracheostomy¹¹. However, it seems that the combination of fiberoptic broncho-scopy and 64-slice CT scan used in our study is an acceptable approach and was sufficiently accurate to detect subglottic stenoses. The ideal duration of follow-up for detecting tracheal stenosis after PCT has not yet been well defined, though most of the Authors believe that 3 months is adequate^{11 20}. In our study, all patients were followed up for 4 months and it is less likely that any tracheal stenosis has been missed. However, the present study had some limitations, the most important being the small number of the patients studied.

In conclusion, the present study revealed that tracheal stenosis occurs in the long-term which may be partly due to tracheal cartilage damage. The stenosis is generally subglottic in nature and is generally mild and not associated with serious and/or life-threatening clinical manifestations. Early decannulation may play a protective role.

Acknowledgements

The Authors thank Farzan Institute for Research and Technology for technical assistance.

References

- 1 Kollef MH, Ahrens TS, Shannon W. *Clinical predictors and outcomes for patients requiring tracheostomy in the intensive care unit*. Crit Care Med 1999;27:1714-20.
- 2 Ciaglia P, Firsching R, Syniec C. *Elective percutaneous dilatational tracheostomy: a new simple bedside procedure; preliminary report*. Chest 1985;87:715-9.
- 3 Freeman BD, Isabella K, Lin N, et al. *A meta-analysis of prospective trials comparing percutaneous and surgical tracheostomy in critically ill patients*. Chest 2000;118:1412-8.
- 4 Dulguerov P, Gysin C, Perneger TV, et al. *Percutaneous or surgical tracheostomy: a meta-analysis*. Crit Care Med 1999;27:1617-25.
- 5 Beltrame F, Zussino M, Martinez B, et al. *Percutaneous versus surgical bedside tracheostomy in the intensive care unit: a cohort study*. Min Anestesiol 2008;74:529-35.
- 6 Byhahn C, Wilke HJ, Lischke V, et al. *Bedside percutaneous tracheostomy: clinical comparison of Griggs and Fantoni techniques*. World J Surg 2001;25:296-301.
- 7 Cantais E, Kaiser E, Le-Goff Y, et al. *Percutaneous tracheostomy: prospective comparison of the translaryngeal technique versus the forceps-dilatational technique in 100 critically ill adults*. Crit Care Med 2002;30:815-9.
- 8 Anon JM, Escuela MP, Gomez V, et al. *Percutaneous tracheostomy: Ciaglia Blue Rhino versus Griggs' Guide Wire Dilating Forceps. A prospective randomized trial*. Acta Anaesthesiol Scand 2004;48:451-6.
- 9 Simpson TP, Day CJE, Jewkes CF, et al. *The impact of percutaneous tracheostomy on intensive care unit practice and training*. Anaesthesia 1999;54:186-9.
- 10 Byhahn C, Wilke HJ, Halbig S, et al. *Percutaneous tracheostomy: ciaglia blue rhino versus the basic ciaglia technique of percutaneous dilatational tracheostomy*. Anesth Analg 2000;91:882-6.
- 11 Raghuraman G, Rajan S, Marzouk JK, et al. *Is tracheal stenosis caused by percutaneous tracheostomy different from that by surgical tracheostomy?* Chest 2005;127:879-85.
- 12 Karvandian K, Mahmoodpoor A, Beig Mohammadi MT, et al. *Internal deviation of tracheal cartilage: A new complication for percutaneous dilatational tracheostomy*. J Med Sci 2007;7:1372-3.
- 13 Hameed AA, Mohamed H, Al-Ansari M. *Experience with 224 percutaneous dilatational tracheostomies at an adult intensive care unit in Bahrain: a descriptive study*. Ann Thorac Med 2008;3:18-22.
- 14 Arabi Y, Haddad S, Shirawi N, et al. *Early tracheostomy in intensive care trauma patients improves resource utilization: a cohort study and literature review*. Crit Care 2004;8:347-52.
- 15 Ahmed R, Rady SR, Mohammad Siddique JI, et al. *Percutaneous tracheostomy in critically ill patients: 24 months experience at a tertiary care hospital in United Arab Emirates*. Ann Thorac Med 2010;5:26-9.
- 16 Ciaglia P, Firsching R, Syniec C. *Elective percutaneous dilatational tracheostomy. A new simple bedside procedure; preliminary report*. Chest 1985;87:715-9.
- 17 Anon JM, Gomez V, Escuela MP, et al. *Percutaneous tracheostomy: comparison of Ciaglia and Griggs techniques*. Crit Care 2000;4:124-8.
- 18 Dollner R, Verch M, Schweiger P, et al. *Long-term outcome after Griggs tracheostomy*. J Otolaryngol 2002;31:386-9.
- 19 Ciaglia P, Graniero KD. *Life-threatening complications from percutaneous dilatational tracheostomy*. Crit Care Med 1992;20:907.
- 20 Hill BB, Zweng TN, Maley RH, et al. *Percutaneous dilatational tracheostomy: report of 356 cases*. J Trauma 1996;41:238-43; discussion 43-4.

Received: August 3, 2010 - Accepted: April 2, 2011

Address for correspondence: Dr. Kasra Karvandian, Department of Anesthesiology, Tehran University of Medical Sciences. E-mail: kassramail@yahoo.com